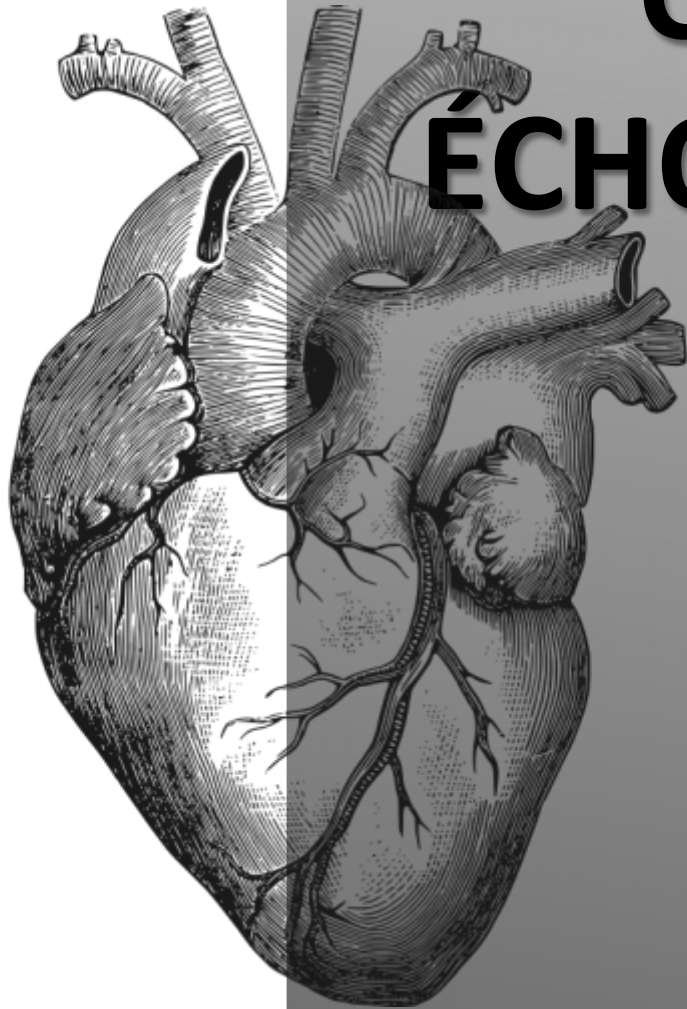




A.C.C.A.



CAS CLINIQUES ÉCHOCARDIOGRAPHIE

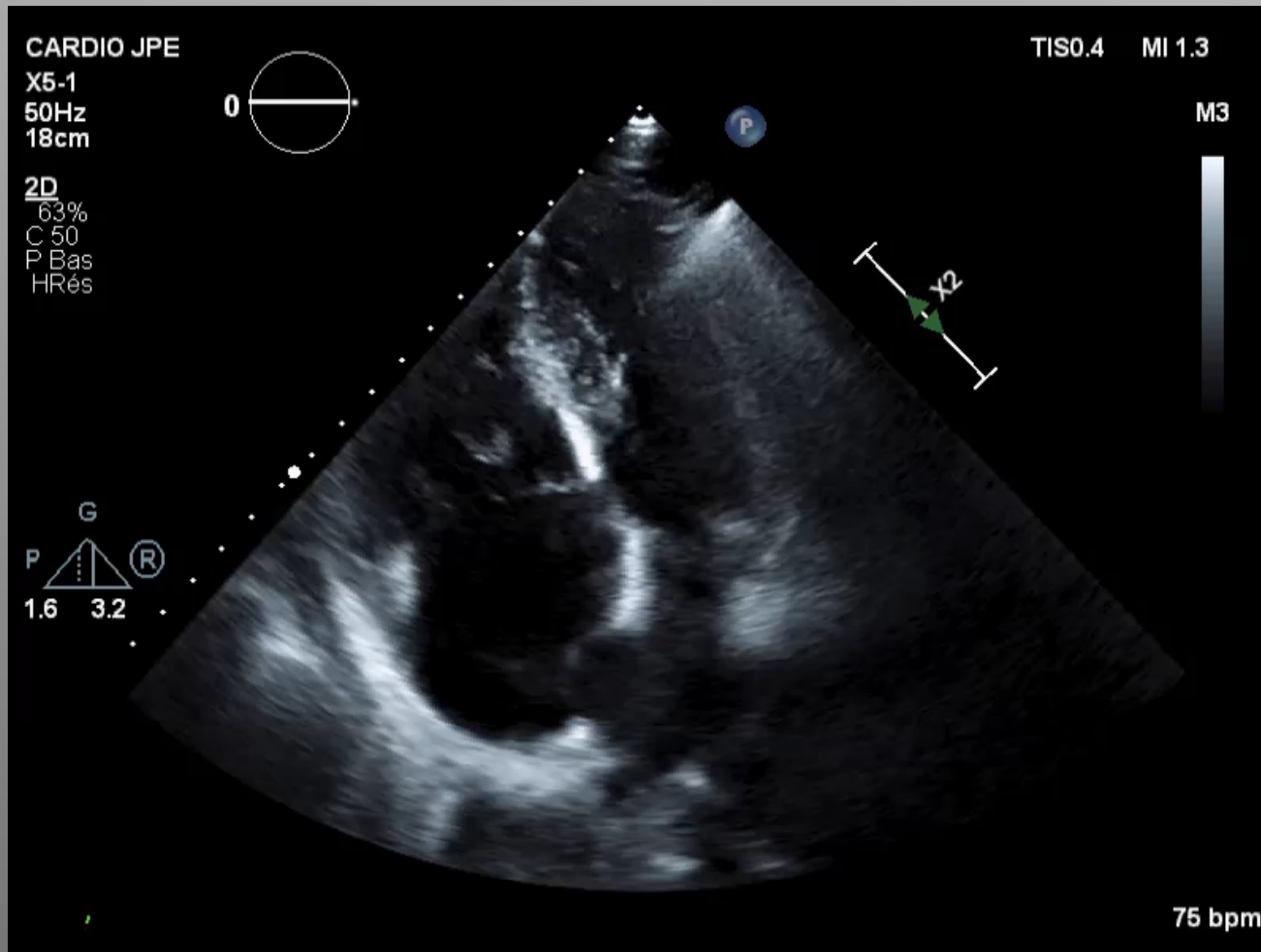
Dr jean Pierre ELBEZE

INSTITUT
A
ARNAULT
TZANCK

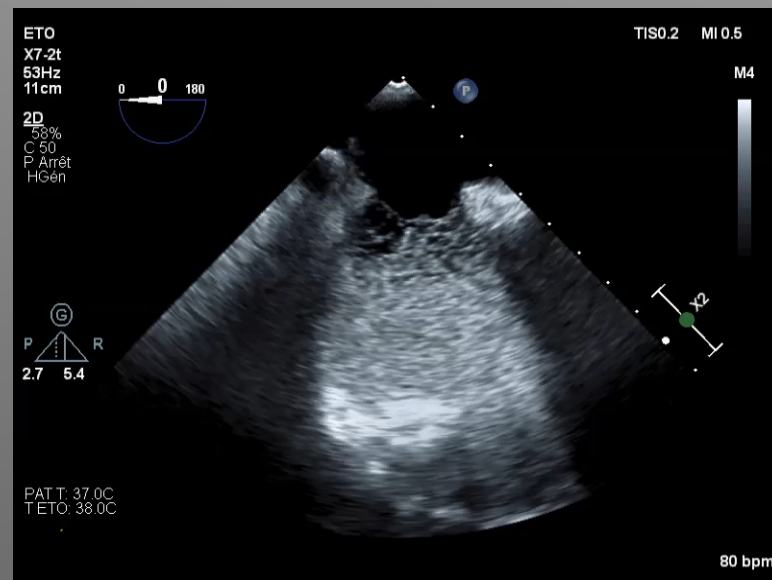
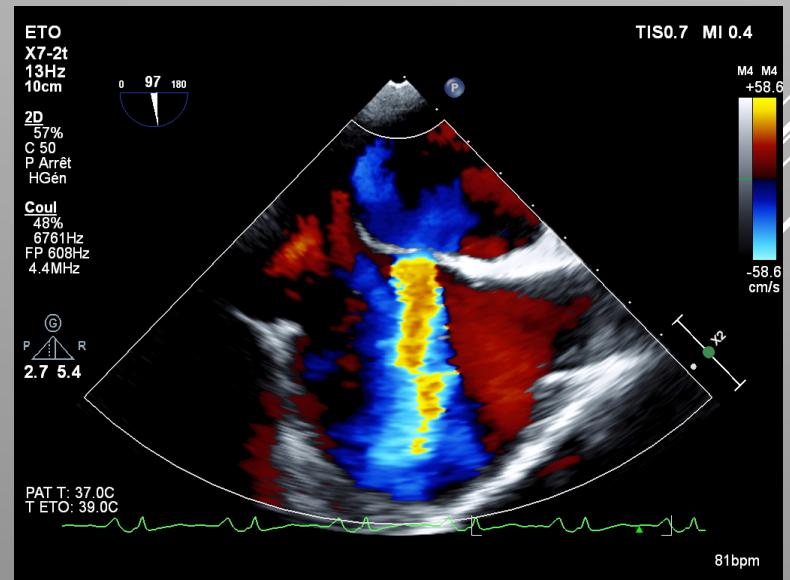
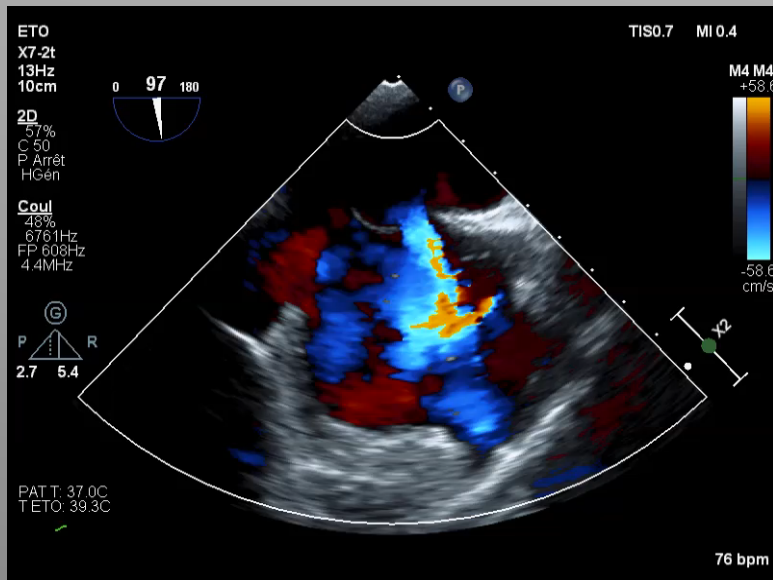
CAS CLINIQUE N°1:

- M. B. 62 ans
 - Février 2017: accident vasculaire cérébral
- 
- A decorative graphic consisting of several parallel white lines of varying thicknesses, slanted diagonally from the bottom-left towards the top-right, located in the lower right quadrant of the slide.

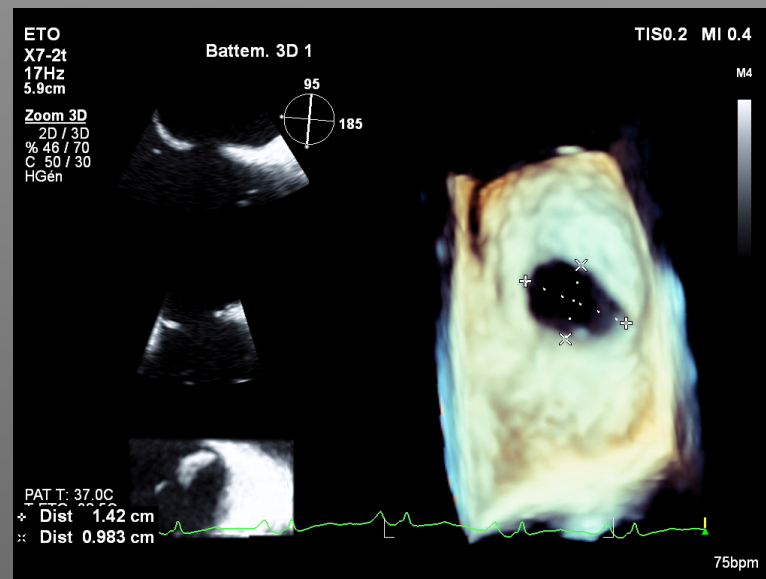
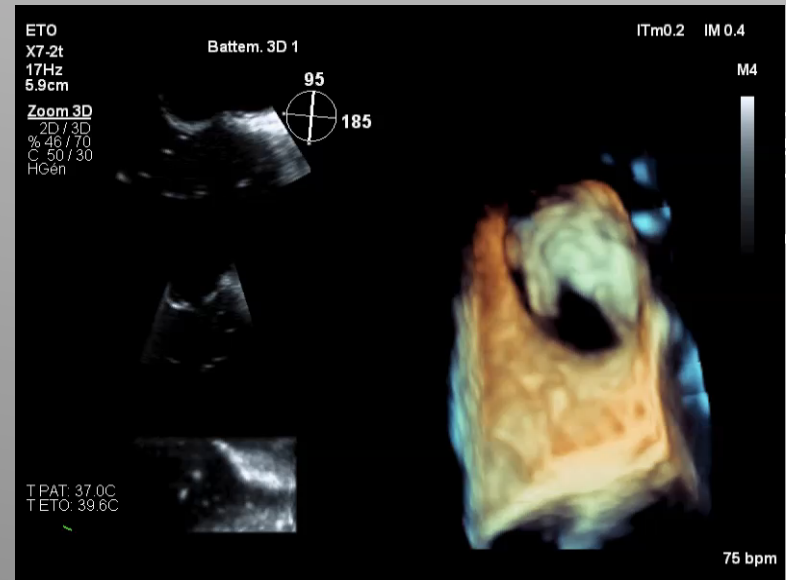
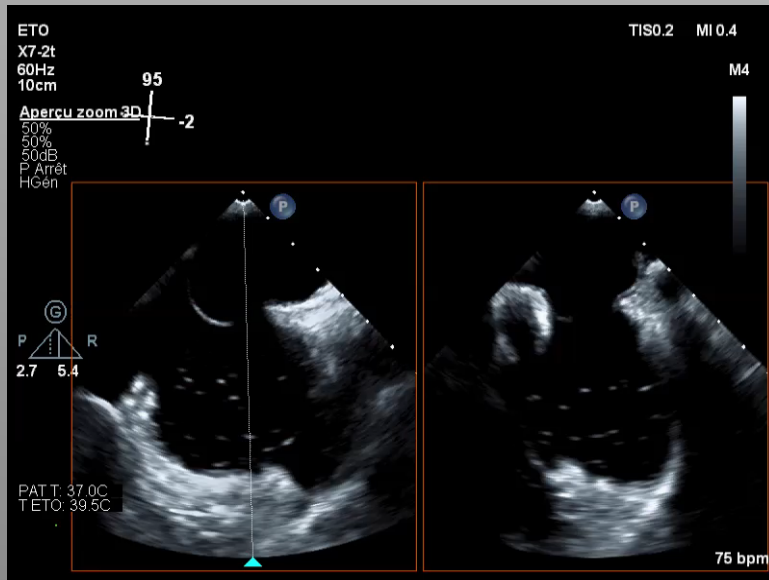
CAS CLINIQUE N°1:



CAS CLINIQUE N°1:

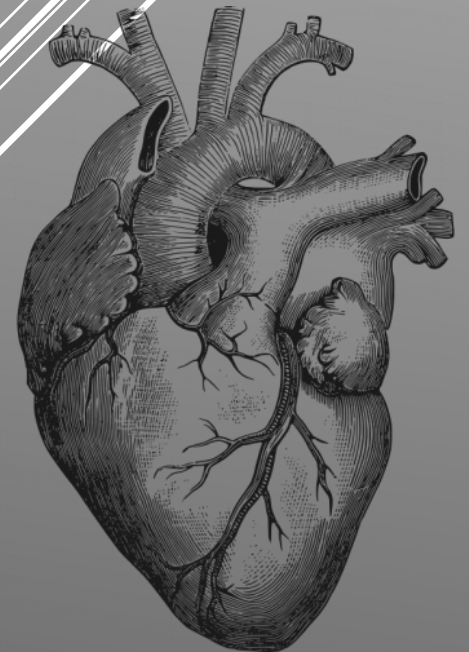


CAS CLINIQUE N°1:



CAS CLINIQUE N°1:

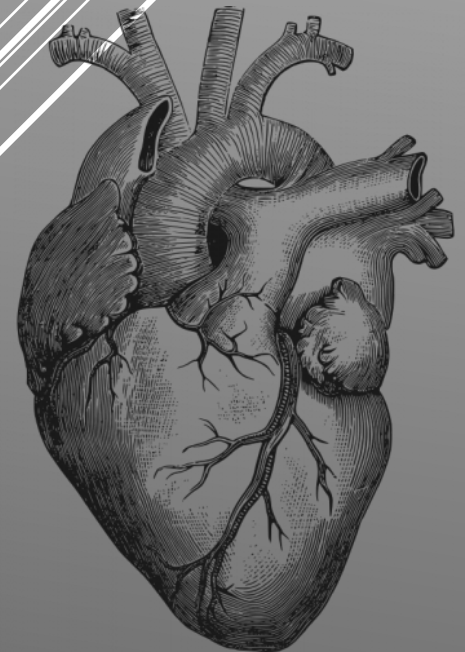
Quel diagnostic ?



CAS CLINIQUE N°1:

Solution

Présence d'une CIA ostium secundum importante





CAS CLINIQUE N°1:

Conduite à tenir

Holter longue durée

Ablation de FA si arythmie

Et fermeture de CIA

