

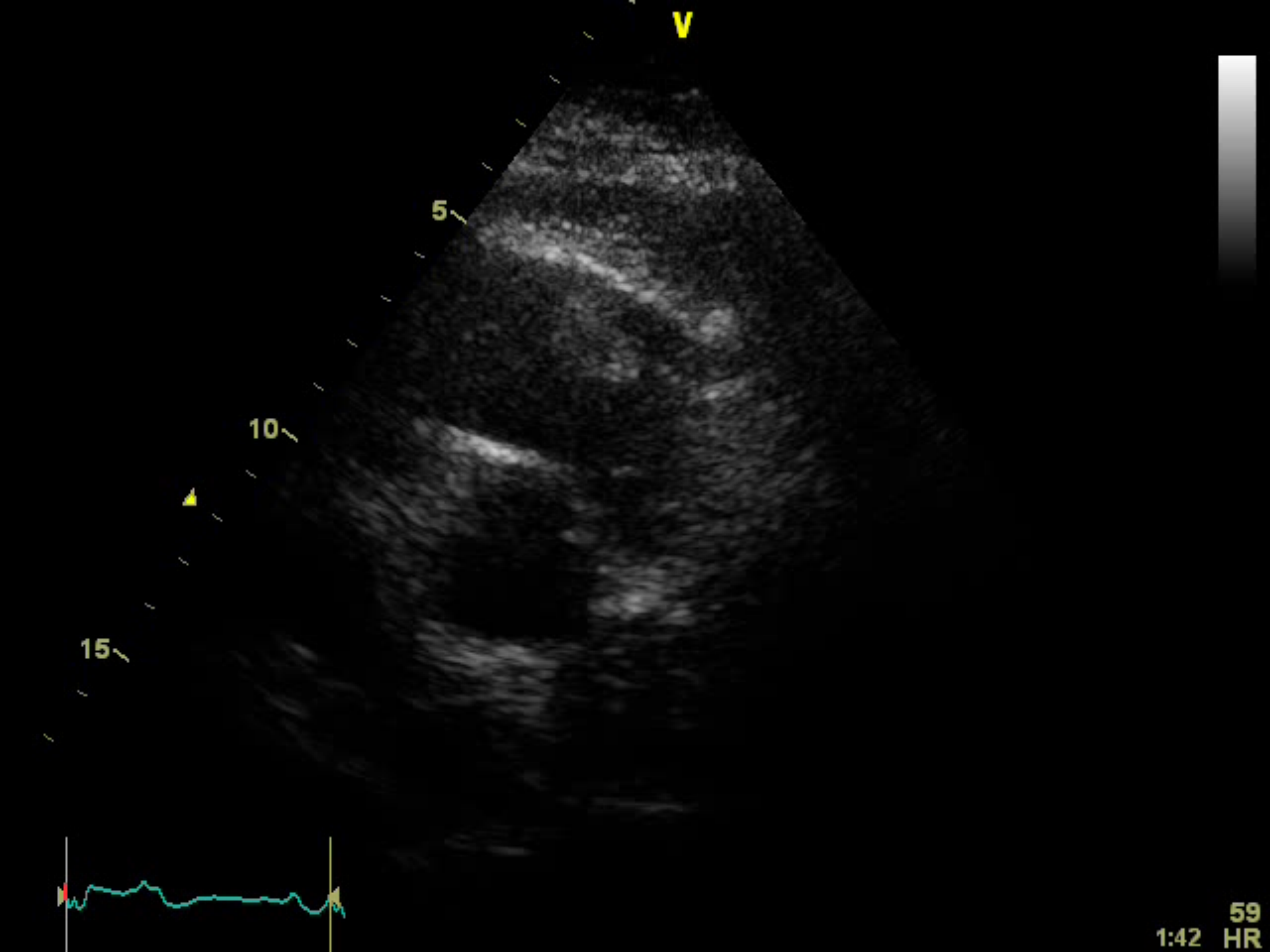
Image anormale de l'infundibulum pulmonaire

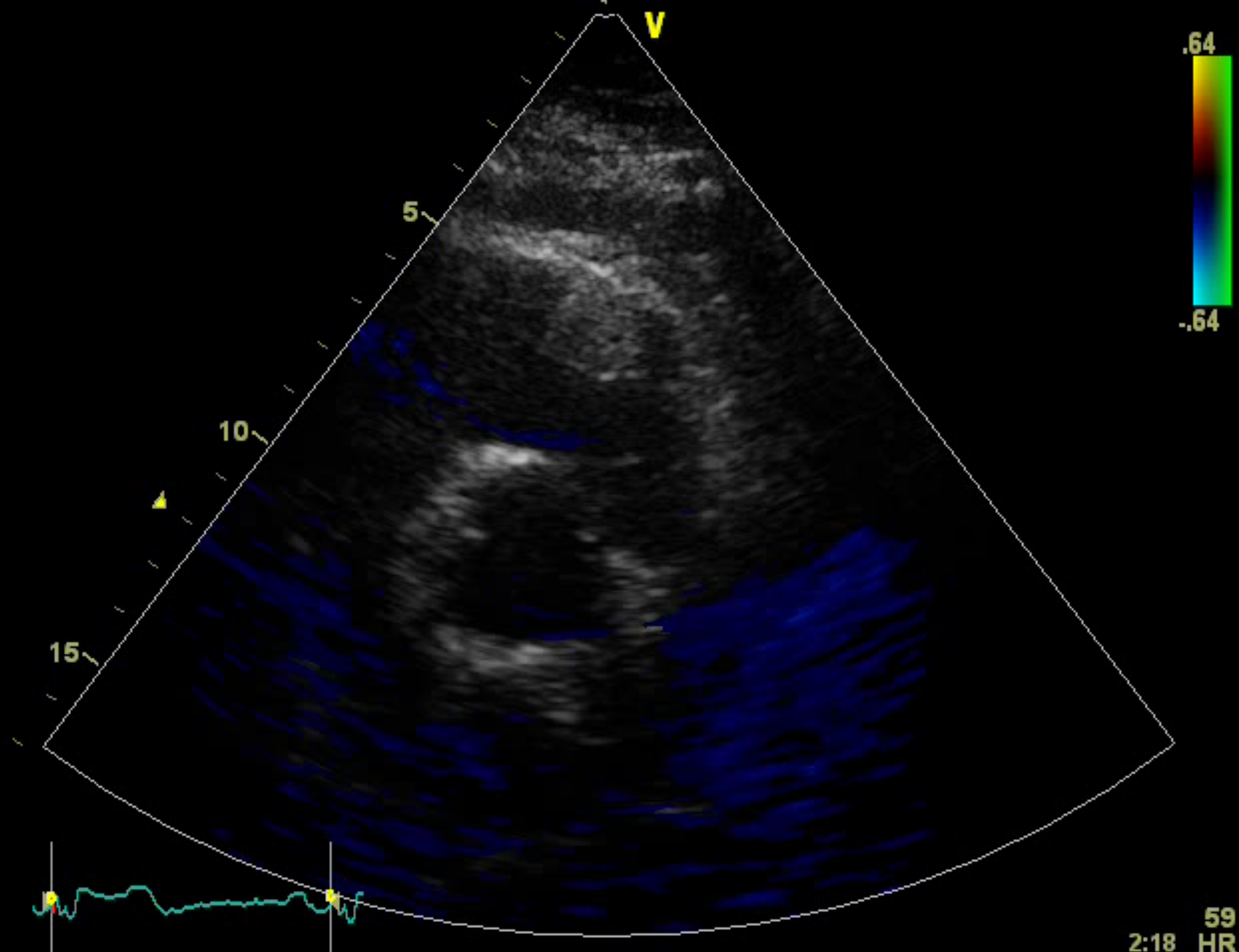
Institut Arnault Tzanck

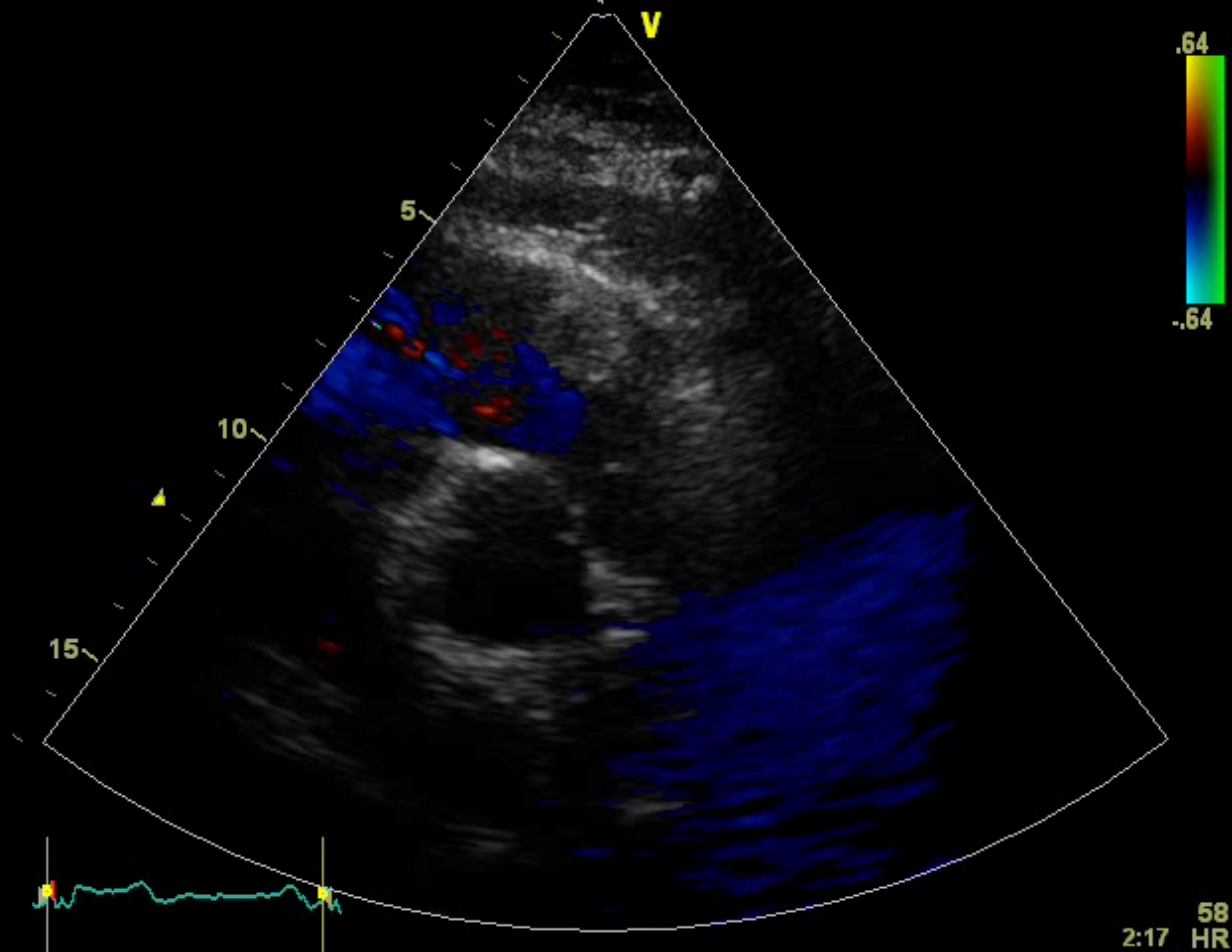
2014

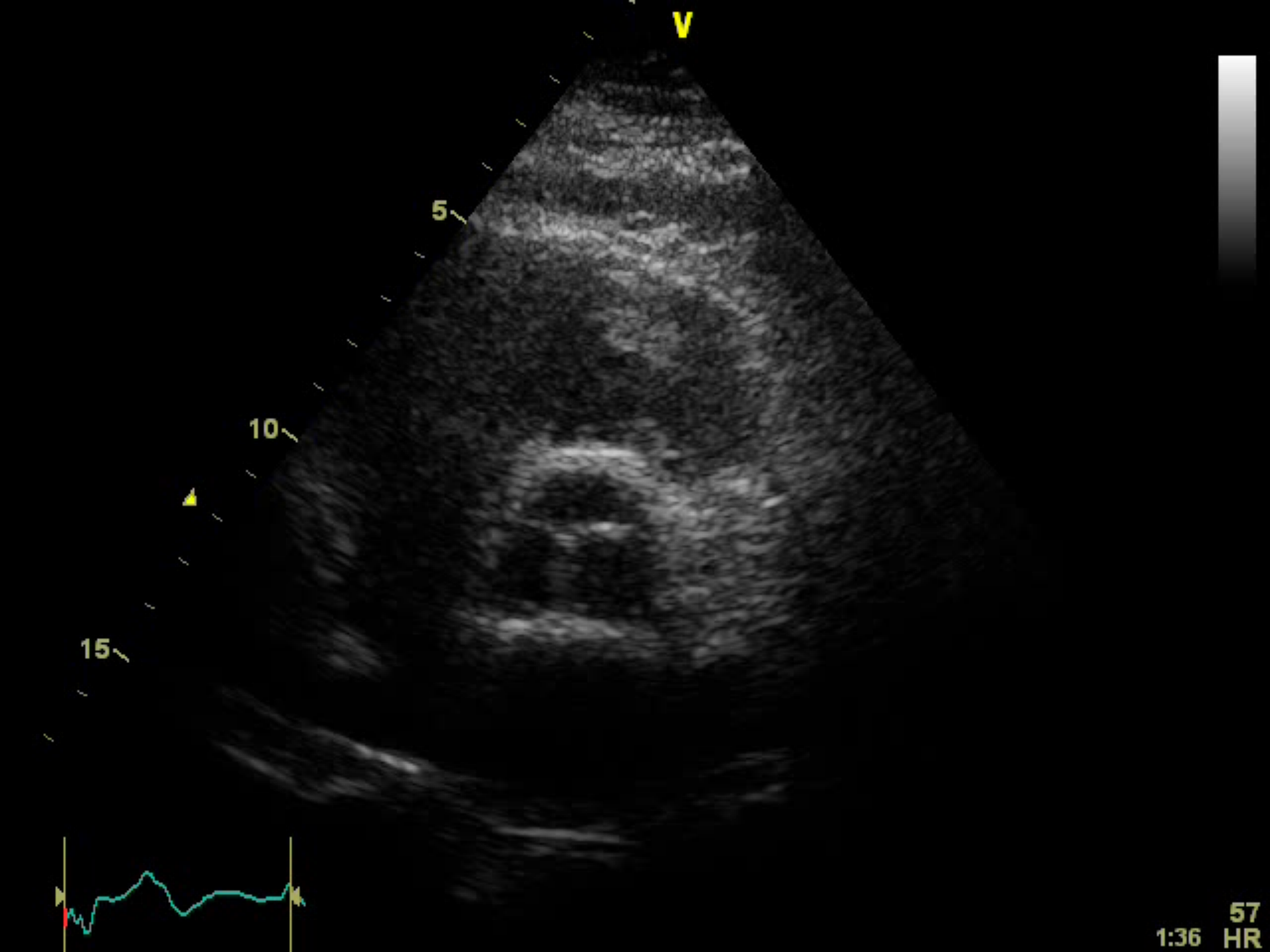
Dr. S

- 2 décembre 1948
- Pas de signe fonctionnel
- Bilan systématique









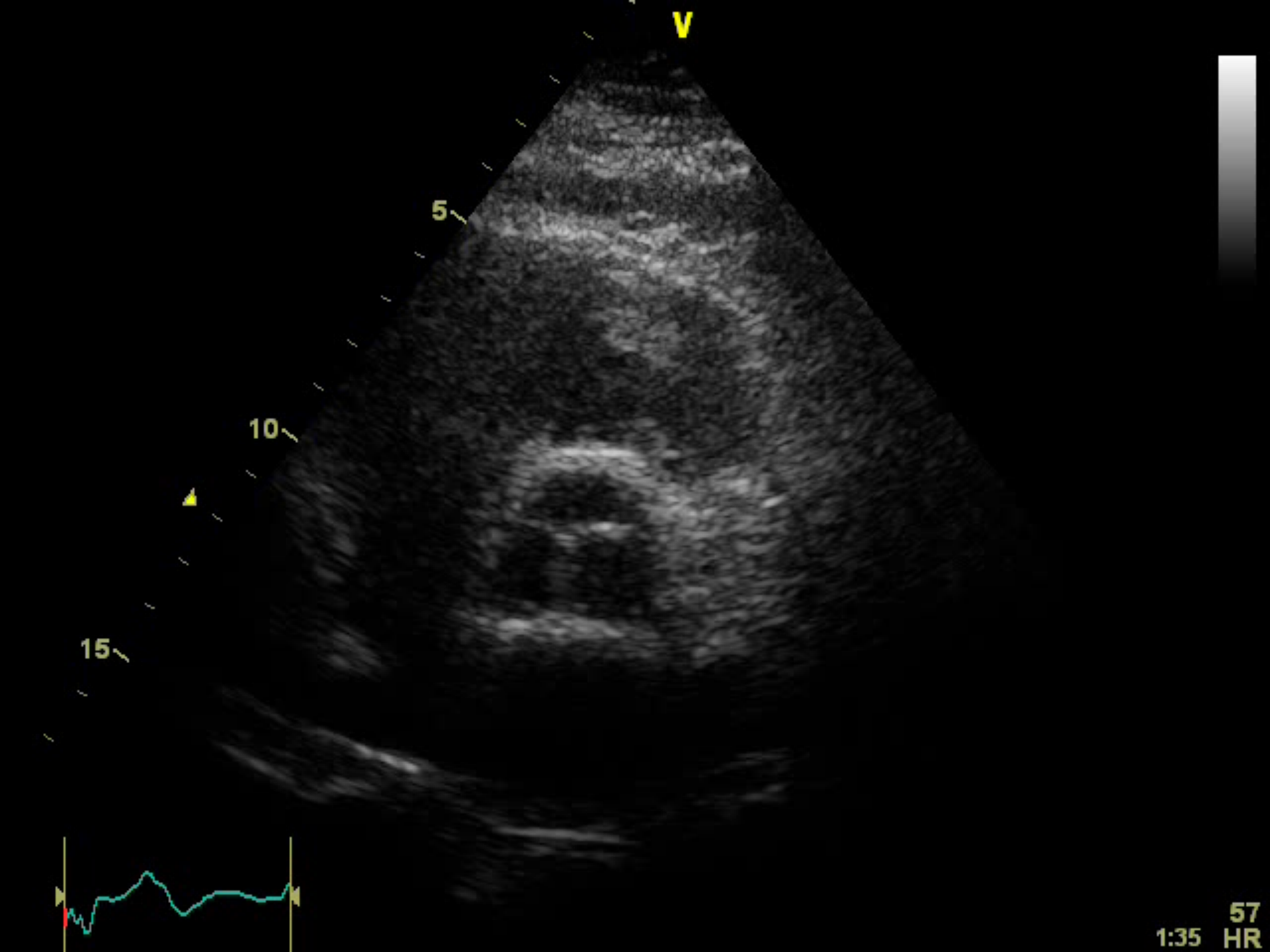
V

5

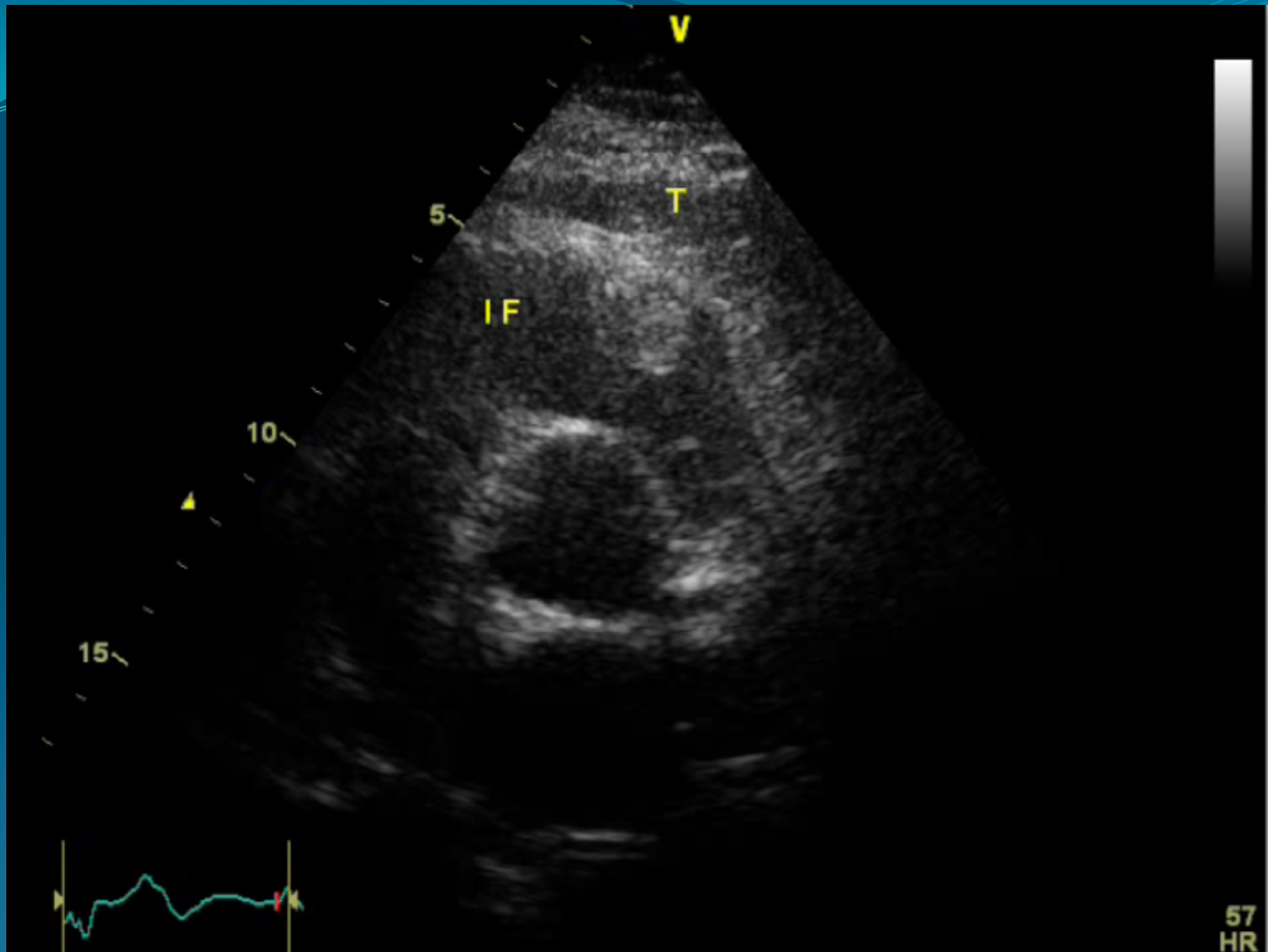
10

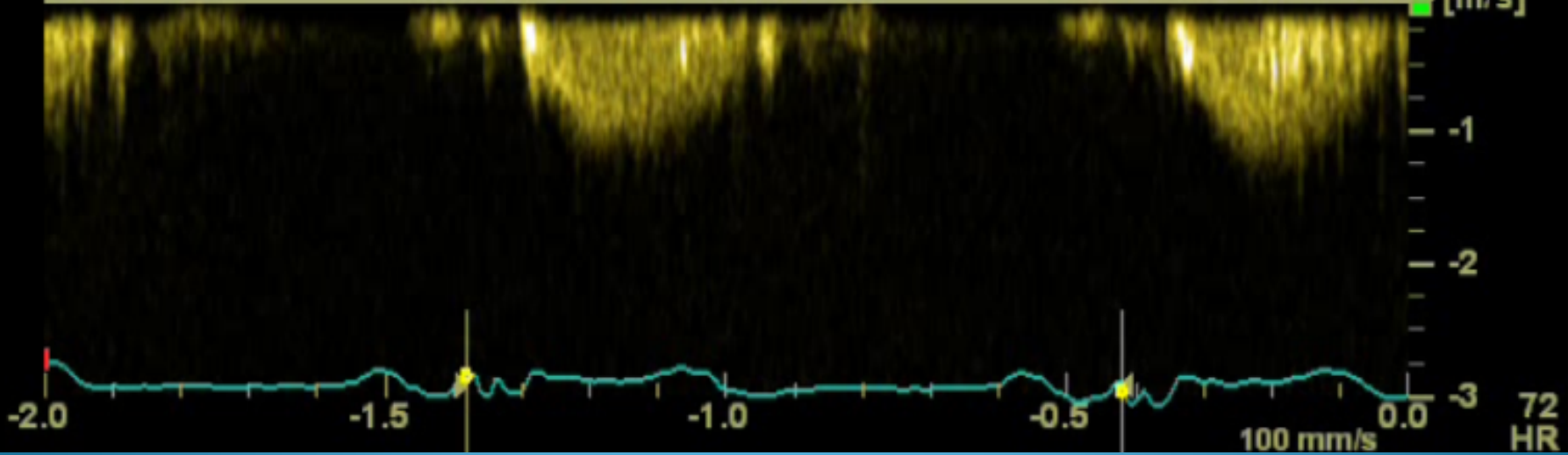
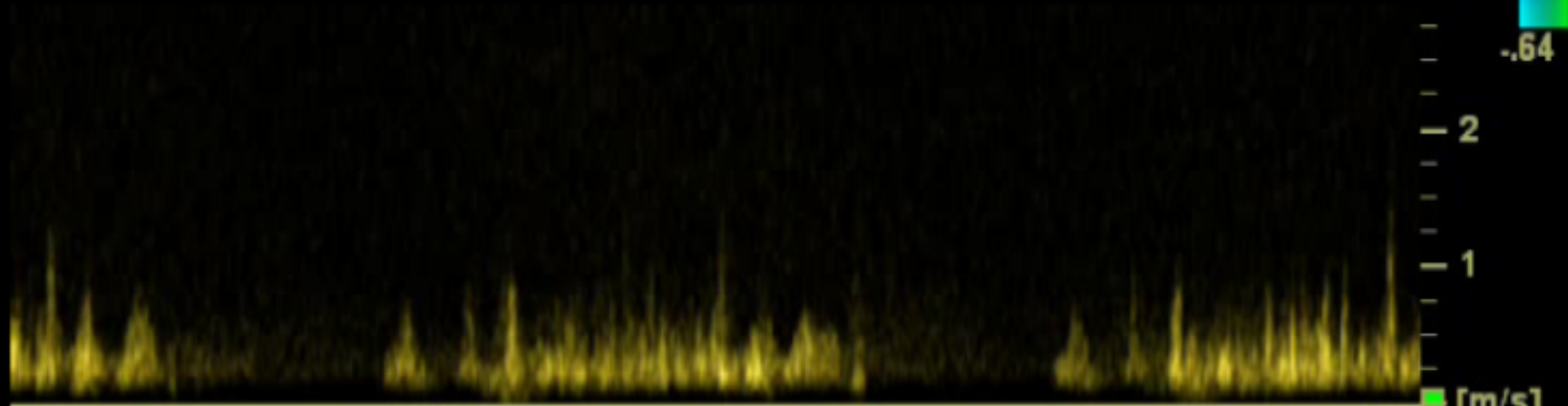
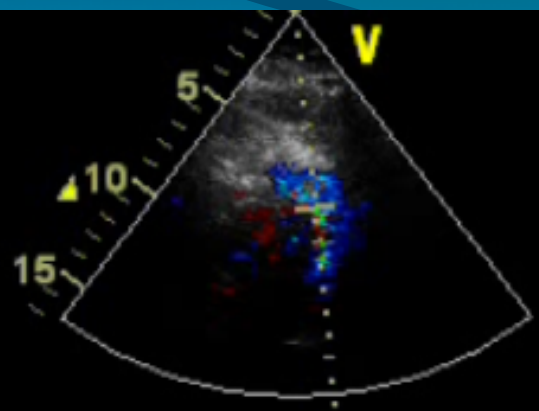
15

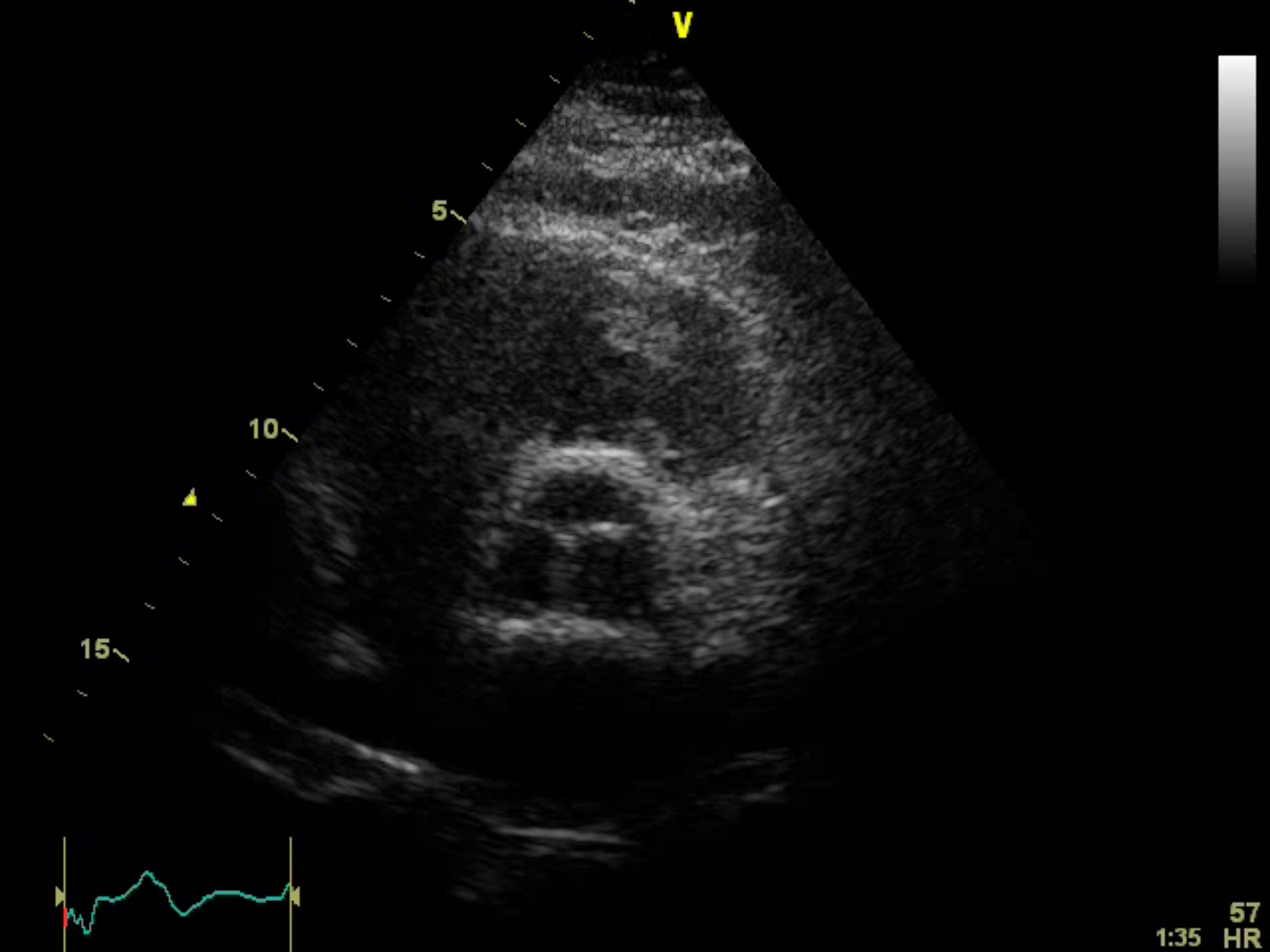
1:36 57 HR



57
HR
1:35







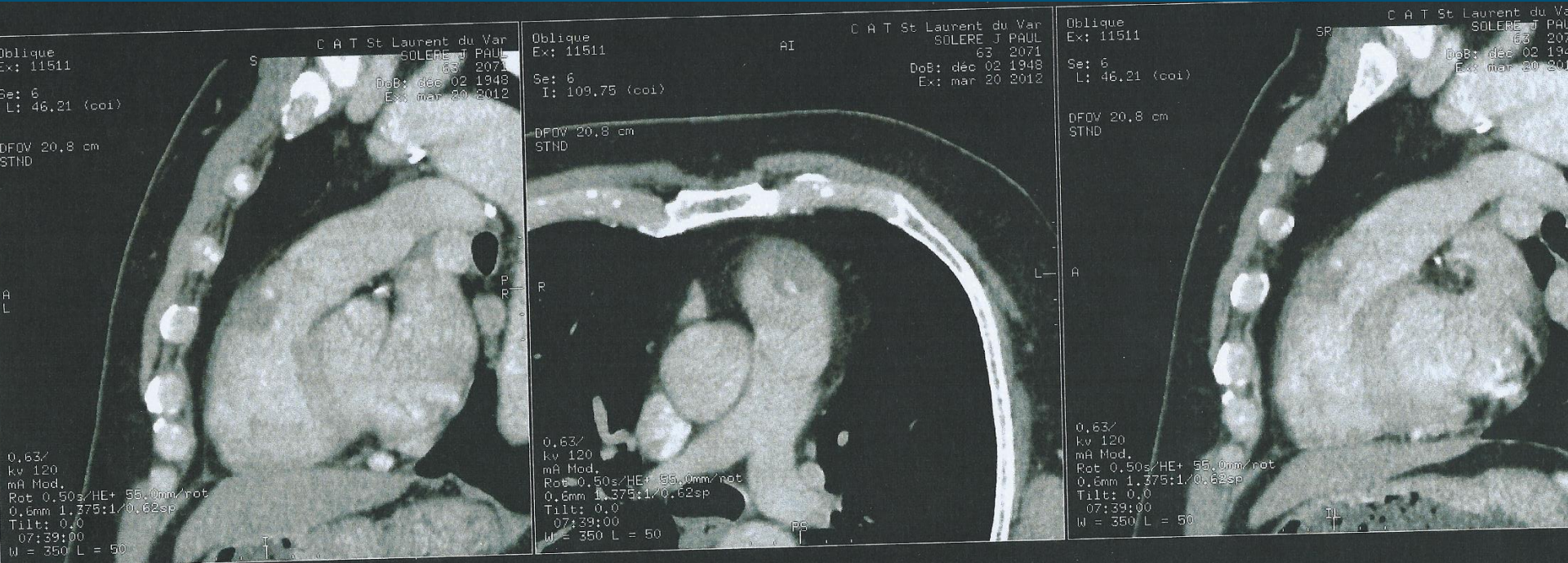
57
HR
1:35

Dr. S

Bilan de médecine interne : pas de néoplasie

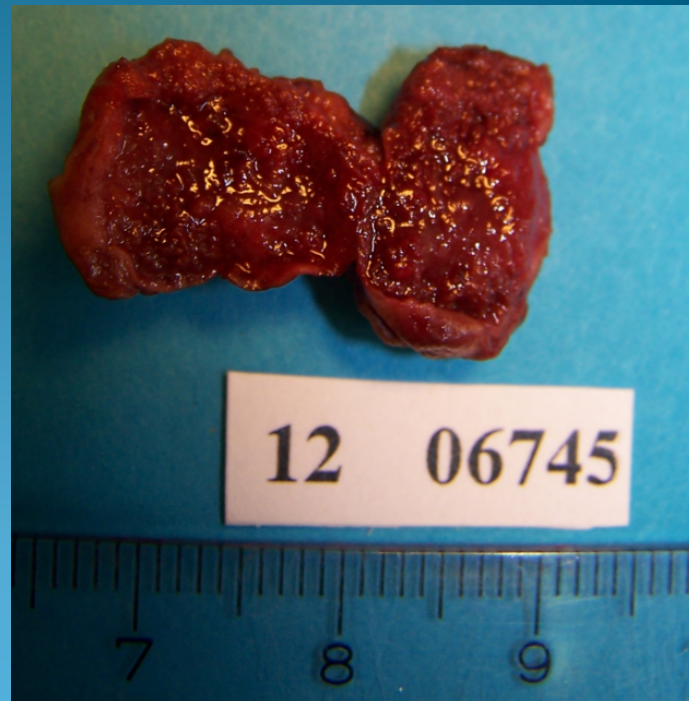
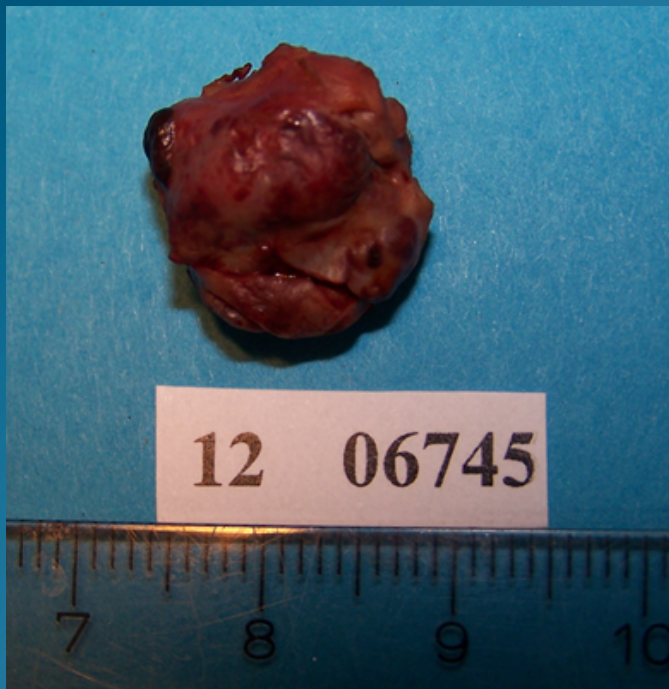- Coronarographie normale
- Coloscopie
- Fibroscopie gastrique
- Body scanner

Dr. S Scanner



Dr. S

- 19/06/2013
- Dr. Tapia : résection tumeur pulmonaire



Dr. S Anapath

- Pas myxome
- Tumeur angiomateuse à développement sous endocardique et myocardique superficiel (Dr. Penot)
 - ➔ Nécessité d'éliminer un angiosarcome
- **Malformation veineuse** appelée **hémangiome caverneux** (Dr. Chalabreysse, Lyon) Anticorps anti-CD34 et CD31 + D240 et Ki67 –