



# UNE CAUSE RARE D'INFARCTUS DU MYOCARDE CHEZ LES SUJETS JEUNES

Dr JP ELBEZE

Monsieur S 17 ans  
Infarctus antéro-septal

CARDIO JPE


X5-1  
50Hz  
16cm  
Z 2.0  
2D  
61%  
C 50  
P Bas  
HRés



TIS0.4 MI 1.3

P

M3

G  
P  (R)  
1.6 3.2

+ Dist 0.948 cm  
× Dist 0.440 cm

109bpm


CARDIO JPE

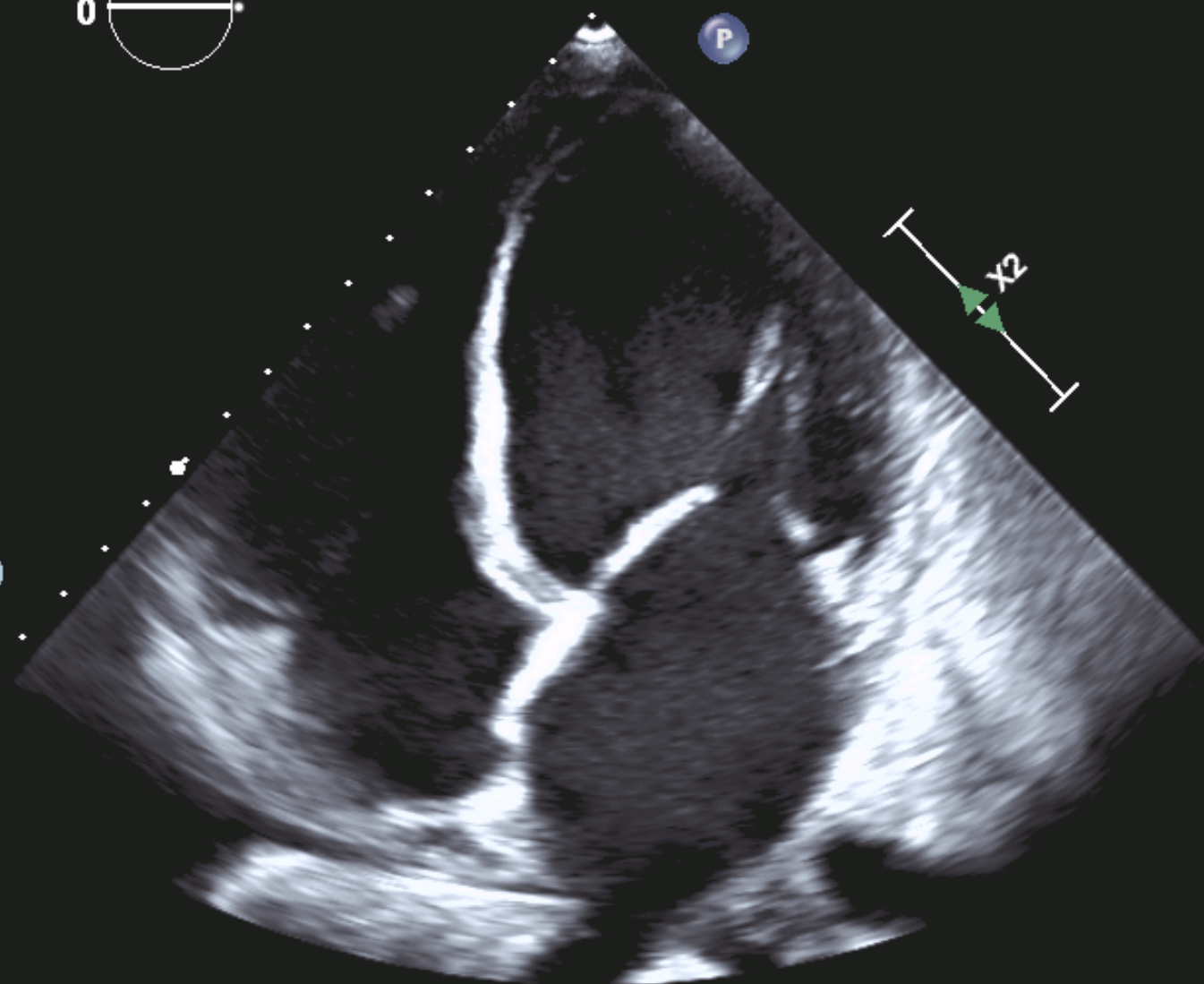
X5-1  
50Hz  
16cm

TIS0.4 MI 1.3

M3

2D  
61%  
C 50  
P Bas  
HRés

G  
P  (R)  
1.6 3.2



110 bpm

CARDIO JPE

X5-1

50Hz

17cm

Z 1.7

2D

61%

C 50

P Bas

HRés



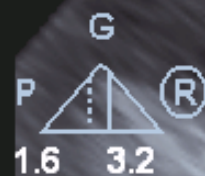TIS0.4

MI 1.3

P

M3

x2



110 bpm



CARDIO JPE

X5-1  
50Hz  
15cm

2D  
62%  
C 50  
P Bas  
HRés

TIS0.4 MI 1.3

M3

G  
P 1.6 3.2 (R)



P

X2

110 bpm

# AKINESIE ANTERO SEPTO APICAL FE 30% SL 3%

